

Dengue Fever Presenting as Bilateral Dengue Maculopathy

UMI KALTHUM MN, WONG HS

Department of Ophthalmology, Faculty of Medicine, Universiti Kebangsaan Malaysia, Jalan Yaacob Latiff, Bandar Tun Razak, 56000 Cheras, Kuala Lumpur, Malaysia.

ABSTRAK

Demam denggi adalah demam yang disebabkan oleh jangkitan virus dan insidens untuk demam denggi bertambah setiap tahun. Manifestasi okular daripada demam denggi adalah pelbagai, termasuk makulopati, pendarahan retina, 'retinal lesions' dan vaskulitis. Penurunan tahap penglihatan dan gangguan penglihatan seperti metamorfopsia adalah presentasi biasa dalam makulopati yang disebabkan oleh demam denggi. Kami melaporkan satu kes yang menarik melibatkan seorang wanita muda dengan makulopati di kedua-dua belah mata disebabkan oleh demam denggi dan diberikan rawatan konservatif. Kisah ini menonjolkan kemungkinan penglibatan okular secara serentak di kedua-dua belah mata di kalangan pesakit yang dijangkiti demam denggi. Doktor perubatan perlu mengambil tahu mengenai komplikasi okular yang disebabkan oleh demam denggi dan menasihatkan pesakit mengenai tanda-tanda yang mungkin berlaku.

Kata kunci: demam denggi, makulopati, metamorfopsia, skotoma, gangguan penglihatan

ABSTRACT

Dengue fever is a common pyrexial-viral infection in the Asian region and the incidence is increasing yearly. There are various ocular manifestations of dengue fever such as maculopathy, retinal hemorrhages, retinal lesions and vasculitis. Reduction in visual acuity and other visual disturbances such as metamorphopsia is the most common presentation of dengue-associated maculopathy. We report an interesting case of a young lady with bilateral maculopathy secondary to dengue fever who was managed conservatively with dramatic visual improvements. This case highlights the possibility of bilateral and simultaneous ocular involvements in patients infected with dengue fever. Both ophthalmologists and physicians need to be aware of ocular complications following dengue fever and advice patients regarding the symptoms.

Address for correspondence and reprint requests: Dr. Umi Kalthum Md Noh, Department of Ophthalmology, Faculty of Medicine, Universiti Kebangsaan Malaysia, Jalan Yaacob Latiff, Bandar Tun Razak, 56000 Cheras, Kuala Lumpur. Tel: 603- 91455981 Fax: 603-91456673. Email: umi_fizul@yahoo.com

Key words: dengue fever, maculopathy, metamorphopsia, scotoma, visual disturbance

INTRODUCTION

Dengue fever is a common mosquito-borne viral infection in the tropical and subtropical regions affecting millions of people yearly. It is a potentially life-threatening condition due to haemorrhagic complications. Ocular manifestation is not common and was previously considered rare. Kalpoor et al. (2006) reported that the most common clinical finding in patients with dengue fever was petechial type of subconjunctival haemorrhages (Kalpoor et al. 2006). Posterior segment involvements were vascular tortuosity and retinal haemorrhages, sparing the macula region (Kalpoor et al. 2006). Other common findings are blot retinal haemorrhages and retinal vessel tortuosity. The patho-mechanism of ocular involvement is not clearly understood, and treatment options for ocular complications of dengue fever are not established (Chang et al. 2007). Management of dengue-related ophthalmic complications are largely conservative. Steroid has been used in selected cases with extensive vasculitis or exudative retinal detachment (Chan et al. 2006). The visual prognosis is good, but most patients have residual scotoma with good Snellen visual acuity. This particular case presented to the ophthalmology unit prior to diagnosis of dengue fever, and highlights the importance and possibility of ocular manifestation of this condition to both the ophthalmologists and physicians. Furthermore, it illustrates that

conservative management in a patient not suitable for steroid therapy is still effective, and should be considered in selected cases, especially when steroid side effects is the main issue.

CASE REPORT

A 37 year old lady presented with a one day history of central scotoma in both eyes. She had persistent fever for one week and noted skin rash three days previously. She was otherwise well and was breastfeeding at the time of presentation.

Ocular examination showed reduced visual acuity of 20/200 in both eyes. Anterior segment examination was unremarkable. The most obvious findings on funduscopy were bilateral macular oedema with small, discrete subretinal deposits and blot retinal haemorrhages. Optic discs and retinal vessels were normal (Figure 1). There were no other peripheral retinal lesions in both eyes.

Laboratory investigations were performed including full blood count, dengue and Chikungunya serology. A diagnosis of dengue fever was made based on low platelet count of $106 \times 10^9/L$, an elevated haematocrit level of 38.7% and positive dengue IgM. Serology for chikungunya was negative. Toxoplasmosis and syphilis serology were negative and tuberculosis was ruled out by negative chest X-ray and Mantoux test. Amsler chart test showed a large area of central scotoma on both eyes. Optical coherence

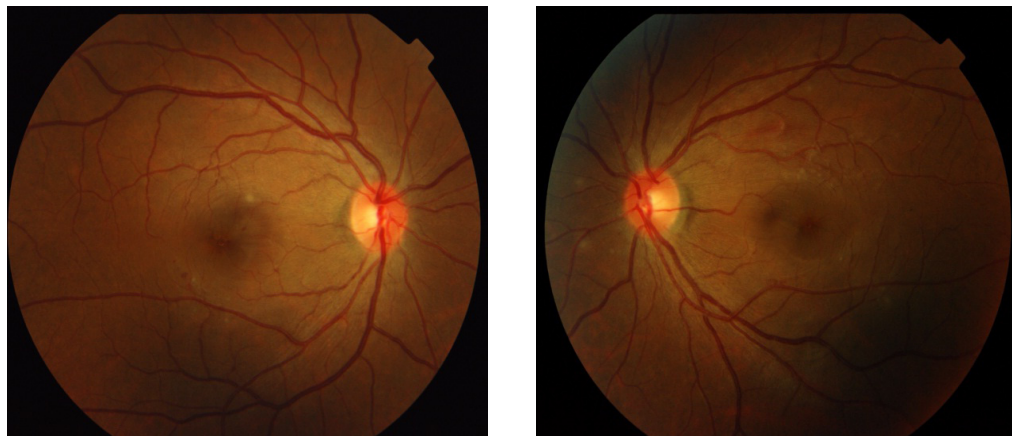


Figure 1: Fundus photograph showing bilateral macula oedema with yellow subretinal deposits and dot haemorrhages

tomography (OCT) demonstrated bilateral subretinal fluid collections (Figure 2). Patient opted not to proceed with fluorescein angiography as she is exclusively breastfeeding at that time.

Intravenous fluid (normal saline 0.3%) was instituted, and the patient recovered from dengue fever without major haemodynamic derangement. She regained her baseline visual acuity at six weeks after her first presentation. However, she still perceived areas of scotoma in her peripheral visual field at one year follow up.

DISCUSSION

Dengue fever is an endemic health issue which raises public health concern due to its dramatic increase in the incidence in recent years. Severe dengue fever known as dengue haemorrhagic fever is life threatening. In endemic areas, dengue is diagnosed by clinical symptoms of fever, typical rash and thrombocytopaenia. However confirmatory diagnosis is based on IgG and IgM serology for antibody

detection, (Buchy et al. 2006) and real-time polymerase chain reaction for dengue RNA serotypes (Lanciotti et al. 1992).

Ocular involvements in association with dengue fever have been reported, mainly of reduction in visual acuity and visual image distortion secondary to macular changes. The visual metamorphosis is thought to arise from subretinal fluid accumulation (Su et al. 2007). The exact patho-mechanism of dengue-related ocular complications is unknown, but it may be attributed to an underlying immunological reaction, which may lead to inflammatory response in retinal tissue and retinal vascular systems. Visual disturbance can be debilitating especially when it occurs bilaterally, and in a young mother such as the present case.

The appearance of ocular symptoms and onset of dengue fever may vary from 2 to 15 days. Typically, ocular manifestations of dengue fever occur one week following the onset of illness, when other symptoms are improving, and correspond to development

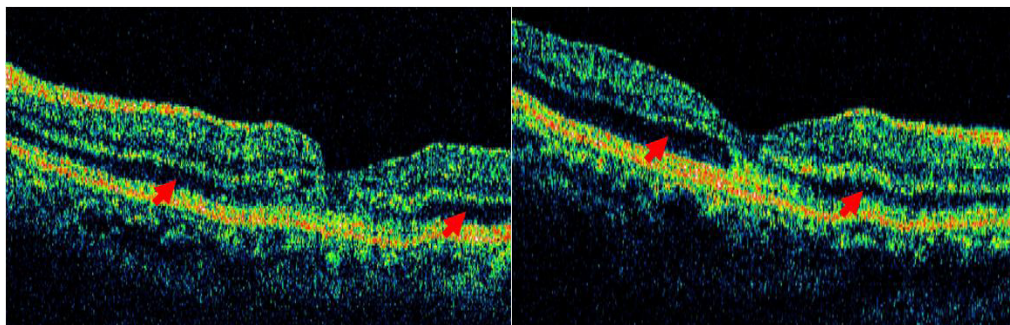


Figure 2: Optical coherence tomography demonstrate subretinal fluid collection on both right and left eyes (arrow)

of immune-complex and antibody formation (Su et al. 2007). This immune-mediated ocular reactions to systemic infection corresponds with production of autoantibodies and deposition of immune complex (Lim et al. 2004). A study utilizing electrophysiology by Chia et al. (2006) found that middle and outer retina are more severely affected compared to the more-spared inner retina at the foveal region (Chia et al. 2006). It has been reported that most patients recover from their visual functions, however occlusive vasculitis from dengue-related vasculopathy may result in permanent visual loss due to development of retinal ischaemia. Our case is unusual as patient presented with ocular symptoms as a presentation of dengue fever, although she noticed the appearance of skin rash three days prior to that. To the best of our knowledge, this is the first report of a patient who presented with dengue maculopathy before the diagnosis of dengue fever was made.

The recovery of dengue maculopathy typically occurs four to six weeks from the onset, but residual scotoma and metamorphopsia is often permanent. Visual acuity typically improves

with resolution of macular oedema and recovery of the dengue fever, however, residual paracentral scotoma is common and may be permanent. It is postulated that the immune-complex deposition at the retinal pigment epithelium and choroid cause structural and permanent damage, (Lanciotti et al. 1992) hence the residual scotoma. Affected patients may need to be counseled regarding the long term effects of residual scotoma and follow up may be necessary in cases of non-resolving subretinal fluid. Teoh et al. (2010) found that different patterns of retinal fluid collection such as foveolitis, diffuse retinal thickening and cystoids macular oedema are useful predictors of visual outcome in dengue-related maculopathy (Teoh et al. 2010). The same study concluded that diffuse type of retinal thickening, independent of extent of oedema predicts shortest period of persistence of scotoma. Optical coherence tomography is also a useful tool in assessing the progression or improvements and as an aide in counseling patients.

Regarding the management of dengue fever, there is no specific treatment for dengue related maculopathy, and

recovery in visual acuity commonly occurs without immunosuppressive treatment. A conservative approach is important in certain cases such as patients who are breastfeeding, pregnant or have contraindications to steroid. However, monitoring and patients' education are equally important. In selected cases of extensive inflammatory reaction to retinal tissue and retinal vessels resulting in exudative retinal detachment or retinal ischaemia, immunosuppressive agents may be necessary. Various treatment regime with immunomodulating agents such as intravenous methylprednisolone, oral steroids, intravitreal triamcinolone and immunoglobulin have been tried (Bascal et al. 2007). Bascal and colleagues observed that treatment of dengue maculopathy with steroids are more beneficial in patients with foveolitis and subretinal fluid accumulation, compared to retinal vaso-occlusive cases (Bascal et al. 2007).

CONCLUSION

Dengue is an endemic viral fever with ocular manifestations that may affect useful vision. Dengue-related maculopathy improves with conservative management, but residual visual disturbance may be permanent. Optical coherence tomography is a useful tool for diagnosis and monitoring of patients with maculopathy. Fluorescein angiogram is important to

confirm presence of ischaemic retina or vasculitis, but may not always be the method of choice for breastfeeding or pregnant patients.

REFERENCES

- Bascal, K., Chee, S.P., Cheng, C.L., Flores, J.V. Dengue-associated maculopathy. *Arch Ophthalmol.* 2007; 125(4): 501- 510
- Buchy, P., Yoksan, S., Peeling, R.W., Hunsperger, E. Laboratory tests for the diagnosis of dengue virus infection. Scientific Working Group (World Health Organization), Report on Dengue, 1-5 October 2006, Geneva, Switzerland
- Chan, D.P.L., Teoh, S.C.B., Tan, C.S.H., Nah, G.K.M., Chee, C.K.L., Lim, T.H. Ophthalmic complications of dengue. The eye institute dengue-related ophthalmic complications workgroup. *Emerging Infect Disease J.* 2006; 12(2): 285- 289
- Chang, J.P.E., Cheng, C.L., Asok, K., Fong, K.Y., Chee, S.P. Visual disturbances in dengue fever: an answer at last? *Singapore Med J* 2007; 48(3): 71- 73
- Chia, A., Luu, C.D., Mathur, R., Cheng, B., Chee, S.P. Electrophysiology findings in dengue- related maculopathy. *Arch Ophthalmol* 2006; 124(10): 1421- 1426
- Kalpoor, H.K., Bhai, S., John, M., Xavier, J. Ocular manifestation of dengue fever in an East India Epidemic. *Can J Ophthalmol* 2006; 41(6): 741- 746
- Lanciotti, R.S., Calisher, C.H., Gubler, D.J., Chang, D.J., Vorndam, A.V. Rapid detection and typing of dengue viruses from clinical samples by using reverse transcriptase-polymerase chain reaction. *J Clin. Microbiol.* 1992; 30 (3): 545-41
- Lim, W.K., Mathur, R., Koh, A., Yeoh, R., Chee, S.P. Ocular manifestations of dengue fever. *Ophthalmology* 2004; 111(11): 2057- 2064
- Su, D.H., Bascal, K., Chee, S.P., Flores, J.V.P., Lim, W.K., Chen, B.C.L., Jap, A.H. Prevalence of dengue maculopathy in patients hospitalized for dengue fever. *Ophthalmology* 2007; 114(3): 1743- 1747
- Teoh, S.C., Chee, C.K., Laud, A., Loh, K.Y., Barkham, T., Ang, B.S. Optical Coherence tomography patterns as predictors of visual outcome in dengue- related maculopathy. *Retina* 2010; 30(3): 390-398